World Journal of Gastrointestinal Surgery

Submit a Manuscript: https://www.f6publishing.com

World J Gastrointest Surg 2025 December 27; 17(12): 113546

DOI: 10.4240/wjgs.v17.i12.113546

ISSN 1948-9366 (online)

REVIEW

Future perspectives in esophageal manometry

Stefan Lucian Popa, Vlad Dumitru Brata, Olga Hilda Orășan, Giuseppe Chiarioni, Abdulrahman Ismaiel, Alexandru Marius Padureanu, Dinu Iuliu Dumitrascu, Miruna Oana Dita, Mara Filip, Traian Adrian Duse, Raphaël Eftimie Spitz, Teodora Surdea-Blaga

Specialty type: Gastroenterology and hepatology

Provenance and peer review: Invited article; Externally peer reviewed.

Peer-review model: Single blind

Peer-review report's classification
Scientific Quality: Grade A, Grade A
Novelty: Grade A, Grade A
Creativity or Innovation: Grade B, Grade C
Scientific Significance: Grade A, Grade A

P-Reviewer: Omullo FP, MD, Senior Researcher, Kenya

Received: August 28, 2025
Revised: October 6, 2025
Accepted: November 11, 2025
Published online: December 27, 2025
Processing time: 119 Days and 15.1 Hours

Stefan Lucian Popa, Abdulrahman Ismaiel, Teodora Surdea-Blaga, Second Medical Department, "Iuliu Hatieganu" University of Medicine and Pharmacy, Cluj-Napoca 400000, Romania

Vlad Dumitru Brata, Department of Gastroenterology, Regional Institute of Gastroenterology and Hepatology "Prof. Dr. Octavian Fodor", Cluj-Napoca 400394, Cluj, Romania

Olga Hilda Orășan, Fourth Department of Internal Medicine, Faculty of Medicine, "Iuliu Hațieganu" University of Medicine and Pharmacy, Cluj-Napoca 400012, Cluj, Romania

Giuseppe Chiarioni, Il Cerchio Med Global Healthcare, Verona Center, Verona 37100, Italy

Alexandru Marius Padureanu, Miruna Oana Dita, Raphaël Eftimie Spitz, Department of General Medicine, Faculty of Medicine, "Iuliu Hatieganu" University of Medicine and Pharmacy, Cluj-Napoca 400000, Cluj, Romania

Dinu Iuliu Dumitrascu, Department of Anatomy, UMF "Iuliu Hatieganu" Cluj-Napoca, Cluj-Napoca 400000, Cluj, Romania

Mara Filip, Cluj County Emergency Clinical Hospital, Cluj County Emergency Clinical Hospital, Cluj-Napoca 400347, Cluj, Romania

Traian Adrian Duse, Department of Surgery, Regional Institute of Gastroenterology and Hepatology "Prof. Dr. Octavian Fodor", Cluj-Napoca 400394, Cluj, Romania

Corresponding author: Vlad Dumitru Brata, MD, Researcher, Department of Gastroenterology, Regional Institute of Gastroenterology and Hepatology "Prof. Dr. Octavian Fodor", Croitorilor St 19, Cluj-Napoca 400394, Cluj, Romania. brata_vlad@yahoo.com

Abstract

Esophageal manometry has undergone significant advancements, transitioning from conventional line tracings to high-resolution manometry with topographic analysis. This evolution has improved the classification and diagnosis of esophageal motility disorders, as defined by the Chicago Classification. However, challenges remain in interpreting borderline cases, assessing esophagogastric junction outflow obstruction, and correlating manometric findings with clinical symptoms. Artificial intelligence (AI) has emerged as a promising tool for enhancing esophageal manometry by enabling automated data analysis, pattern recognition, and predictive modeling. Future perspectives include the integration of AI for automated analysis, refinement of pressure topography metrics, and

incorporation of adjunctive testing such as functional luminal imaging probe technology. Additionally, novel catheter designs and ambulatory manometry may enhance diagnostic accuracy and patient comfort. Integrating manometry findings with biomechanical models and machine learning techniques may support the development of more personalized management strategies. This review explores current and emerging technologies and their potential impact on the future of esophageal manometry, aiming to improve diagnostic precision and therapeutic outcomes in esophageal motility disorders.

Key Words: Esophageal manometry; High-resolution manometry; Motility disorders; Artificial intelligence; Translational challenges

©The Author(s) 2025. Published by Baishideng Publishing Group Inc. All rights reserved.

Core Tip: Esophageal manometry continues to evolve beyond conventional techniques, with high-resolution manometry, adjunctive tools such as functional luminal imaging probe, and emerging artificial intelligence (AI) applications, paving the way for more precise, automated, and clinically meaningful assessments. This review highlights how integrating advanced metrics, novel technologies, and AI may overcome current diagnostic limitations and contribute to a more personalized management of esophageal motility disorders.

Citation: Popa SL, Brata VD, Orășan OH, Chiarioni G, Ismaiel A, Padureanu AM, Dumitrascu DI, Dita MO, Filip M, Duse TA, Eftimie Spitz R, Surdea-Blaga T. Future perspectives in esophageal manometry. *World J Gastrointest Surg* 2025; 17(12): 113546
URL: https://www.wjgnet.com/1948-9366/full/v17/i12/113546.htm
DOI: https://dx.doi.org/10.4240/wjgs.v17.i12.113546

INTRODUCTION

Esophageal manometry is a cornerstone diagnostic modality for evaluating esophageal motility disorders. Since its inception in the mid-20th century, manometric techniques have evolved significantly, particularly with the advent of high-resolution esophageal manometry (HREM), which has refined the characterization of esophageal pressure topography and facilitated the development of standardized classification systems, most notably the Chicago Classification (CC)[1-3]. These advancements have improved diagnostic precision and fostered a more nuanced understanding of esophageal pathophysiology[4].

Yet, despite these achievements, significant limitations persist: Interobserver variability, imperfect symptom correlation, and difficulty interpreting borderline or atypical motility patterns[5]. These challenges highlight the need for novel approaches that move beyond manual interpretation and fixed diagnostic thresholds toward data-driven, adaptive tools capable of capturing physiological complexity.

Recent technological developments and integrative approaches show strong potential for addressing these limitations and expanding the clinical applications of esophageal manometry[6]. Innovations such as high-resolution impedance manometry (HRIM)[7], artificial intelligence (AI)-based interpretation[8], functional luminal imaging probe (FLIP)[9], and ambulatory manometric monitoring are poised to redefine the landscape of esophageal motility assessment. These technologies not only offer improved spatial and temporal resolution but also provide adjunctive functional data that may yield greater insight into the mechanisms underlying esophageal symptoms such as dysphagia, chest pain, and regurgitation[10].

Furthermore, the integration of manometric findings with advanced imaging, endoscopic techniques, and biomarker profiling may pave the way for a more holistic, patient-centered approach to the diagnosis and management of esophageal motility disorders. The evolving understanding of the esophagogastric junction (EGJ) as a dynamic, multifunctional barrier rather than a static anatomical structure underscores the need for more sophisticated tools capable of capturing its complex behavior under physiological and pathophysiological conditions[11,12].

At the same time, there is growing interest in using AI and advanced data analysis to make esophageal manometry easier to interpret and more consistent[13]. These technologies can help reduce uncertainty in diagnosis and may, over time, also help identify which patients could benefit from certain types of interventions or closer monitoring based on their symptom profiles. In the future, such tools may enable a shift from static, one-time measurements to continuous, real-time assessments that better reflect patients' daily symptoms and real-life experiences.

Given the fast pace of technological progress and the growing clinical demand for accurate and actionable motility diagnostics, a focused evaluation of new tools and evolving concepts in esophageal manometry is both timely and necessary. This includes technologies such as HRIM, AI-assisted interpretation, and automated pattern recognition, which aim to enhance diagnostic accuracy and consistency. At the same time, new conceptual approaches—such as linking manometric data to symptom patterns and real-life function—are reshaping how results inform clinical decisions. Assessing these advances requires not just technical validation, but also evidence of clinical impact, workflow integration, and benefits for patient care. This review aims to explore the current limitations of conventional manometry, highlight key advancements in the field, and examine future directions with a focus on their potential to transform clinical practice.

By synthesizing recent developments and anticipating future challenges, this article seeks to provide clinicians and researchers with a comprehensive perspective on the evolving role of esophageal manometry in the diagnosis and management of esophageal motility disorders.

HISTORY

The study of esophageal motor function began with François Magendie, who, in the late 18th century, described the three phases of swallowing. Through animal experiments involving simple tube insertion into the esophagus, he observed bolus movement, anticipating more precise physiological approaches[14]. The progress of esophageal manometry along the years is illustrated in Figure 1.

In 1880s, Kronecker and Meltzer[15] conducted the first pressure-based studies of deglutition. Using small rubber balloons placed in the esophagus of anesthetized animals and connected to a water-filled system linked to a kymograph (a device that records pressure or movement over time as a wave-like trace), they recorded pressure variations during swallowing. Their setup demonstrated that peristaltic waves were reflexively and sequentially organized along the esophageal body.

In the 1950s, Hightower *et al*[16] refined these methods using fluid-filled polyethylene catheters and external strain-gauge transducers. This system, which allowed continuous pressure recording without luminal obstruction, enabled the identification of basal pressures, pharyngeal contraction dynamics, and the high-pressure zone of the pharyngoesophageal junction.

Building on this, Millhon *et al*[17] introduced in 1968 a direct intraluminal probe incorporating miniature semiconductor strain gauges. These transducers, embedded at fixed intervals in a soft silicone tube, recorded absolute localized pressures with excellent sensitivity and without the need for perfusion. The probe was radiopaque, temperature-compensated, and allowed reproducible measurements across multiple sessions, enhancing both clinical and physiological studies.

The capillary infusion system described by Arndorfer *et al*[18] employs stainless steel catheters continuously perfused with reboiled distilled water, maintained by compressed nitrogen at a constant pressure. This setup enables precise detection of rapid esophageal pressure changes and provides a superior dynamic response compared to traditional water-perfused catheter systems.

Subsequent technical improvements included miniaturization, expansion of longitudinal sensor arrays, and digitization of data. However, the most transformative advance in manometry came with HREM, pioneered by Clouse *et al*[10]. In 2000, Clouse *et al*[10] published a landmark study introducing topographical analysis of esophageal pressure using 21 intraluminal sensors spaced at 1-cm intervals. This setup allowed the creation of three-dimensional pressure plots, integrating spatial and temporal dimensions of peristaltic activity. For the first time, esophageal pressure could be interpreted as a continuous surface, unveiling segmental characteristics of peristalsis and facilitating the visualization of complex motility patterns. Compared to the conventional four-sensor method, topographical manometry provided superior diagnostic accuracy, particularly in distinguishing severe motility disorders such as achalasia. Furthermore, Clouse's method enabled the identification of incomplete lower esophageal sphincter (LES) relaxation that went undetected by conventional approaches and allowed more precise localization of the LES, crucial for pH monitoring probe placement. Importantly, these advances stemmed not only from increased sensor density but also from the novel visual display of data, which facilitated interpretation and reduced operator-dependent errors.

Clouse's work fundamentally shifted the paradigm of esophageal manometry from line-based tracing to a comprehensive, topographic approach, laying the foundation for HREM as the new clinical standard.

In 2008, the CC provided a standardized interpretation framework for HREM, enhancing reproducibility and diagnostic consistency[19,20]. The addition of impedance measurement further enabled the simultaneous evaluation of bolus transit[21].

HREM

HREM has replaced conventional techniques as the preferred diagnostic tool for assessing esophageal motility, particularly in patients with symptoms such as dysphagia or chest pain[22,23]. Unlike older methods, HREM captures pressure activity across the entire esophagus with high spatial resolution, offering real-time visualization of motor patterns from the upper esophageal sphincter to the EGJ[24,25]. This detailed view allows for more accurate characterization of peristaltic activity and sphincter relaxation.

The standard protocol begins with ten single water swallows, usually with the patient in a supine position. Following this initial phase, the catheter is maintained in place and the same swallowing sequence is repeated with the patient seated upright, allowing for comparison of motility patterns across both postures[20]. When findings are inconclusive, additional swallows in a secondary position, along with provocative tests like multiple rapid swallows (MRS) or rapid drink challenge (RDC), are used to clarify the diagnosis. In some cases, complementary tools such as a timed barium esophagogram (TBE) or FLIP may be required to confirm more difficult manometric patterns such as EGJ outflow obstruction (EGJOO) or peristaltic disorders[20,25].

The output of HREM is presented as a topographic color plot, where variations in pressure are translated into visual gradients along the esophagus. By replacing traditional line tracings with spatially continuous pressure maps, HREM reduces interobserver variability and supports more consistent diagnostic assessments[26]. Its incorporation into clinical

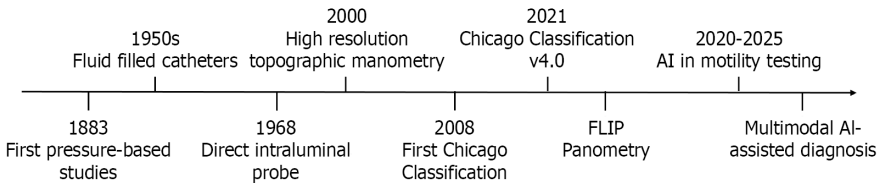

Figure 1 Evolution of esophageal manometry throughout the years. FLIP: Functional luminal imaging probe; AI: Artificial intelligence.

practice has simplified the evaluation process and significantly improved the diagnostic precision in detecting esophageal motor abnormalities[27].

CC

First introduced in 2008, the CC has become the international reference standard for interpreting data from HREM[19]. Currently in its fourth iteration, published in 2021, this framework provides a structured approach for categorizing primary esophageal motility disorders based on objective pressure metrics[20]. Its primary role is to guide the diagnosis of neuromuscular dysfunctions of the esophagus by analyzing esophageal peristalsis and the relaxation of the EGJ. The classification is particularly valuable in distinguishing between disorders of the EGJ outflow and those related to impaired peristalsis[25]. CC v4.0 introduces a structured yet adaptable diagnostic framework that allows for a degree of flexibility, particularly in cases where a definitive diagnosis can be reached following the initial ten test swallows, regardless of whether these are performed in the supine or upright position. The system is conceptualized as a hierarchical decision pathway, where each stage building on the results of the previous one, integrates clinical context and supportive testing where appropriate[20,25].

This classification framework delineates two major diagnostic categories based on the underlying physiological abnormality. The first category includes disorders of the EGJ, despite normal or variable patterns of esophageal peristalsis. This group encompasses achalasia types I, II and III, as well as EGJOO[20,25].

The second category consists of disorders related to ineffective or uncoordinated esophageal peristalsis, in the context of normal EGJ relaxation. These include absent contractility, distal esophageal spasm (DES), hypercontractile esophagus and ineffective esophageal motility (IEM)[28].

Manometric evaluation focuses on a set of standard pressure metrics. The integrated relaxation pressure (IRP) reflects how well the LES relaxes during swallowing and helps identify outflow obstruction. The distal contractile integral (DCI) measures the strength and duration of esophageal contractions in the distal segment. Distal latency is used to assess the timing of peristaltic waves and to help identify spastic contractions, while panesophageal pressurization (PEP) refers to a uniform, simultaneous increase in pressure along the entire length of the esophagus, typically observed in impaired EGJ outflow. Together, these metrics are fundamental to classifying motility disorder using HREM[19,28,29].

Disorders of EGJ outflow include achalasia, which is subclassified into three phenotypes. Impaired relaxation of the LES is present in all three types. In type I achalasia, there is complete aperistalsis. In type II, aperistalsis is also present, but PEP is additionally observed. Type III achalasia is characterized by premature, spastic contractions[30]. EGJOO falls within the same category but is distinguished from achalasia by the presence of preserved peristalsis, making the diagnosis more nuanced and often requiring adjunctive testing[20].

By contrast, peristaltic abnormalities involve conditions such as absent contractility, where no effective swallows are observed, and DES or hypercontractile esophagus, both featuring disordered, exaggerated contractions[25,31]. IEM completes this spectrum, marked by weak or failed peristalsis in the context of normal EGJ function[32].

Although HREM provides a precise assessment of esophageal motor function, its interpretation should not occur without taking the patients' symptoms into account. The clinical relevance of manometric findings depends strongly on the correlation with patient symptoms. Several motility patterns, such as EGJOO or hypercontractile esophagus, may appear on HREM even in asymptomatic individuals, raising concerns about potential overdiagnosis if clinical context is ignored[33,34]. To address this, the CC v4.0 emphasizes the need to integrate manometric results with symptom presentation, particularly in cases of dysphagia or non-cardiac chest pain[20].

Catheter technology

The choice of catheter used in esophageal manometry plays a critical role in both diagnostic precision and patient experience. There are two main technologies currently in use: Water perfused and solid-state catheters, each of these coming with advantages and disadvantages that influence their suitability across clinical settings[35].

Water-perfused catheters, based on a system of open side ports and external pressure transducers, are generally more accessible in terms of cost and reusability. However, they require extensive preparation, are sensitive to motion artefacts and depend on continuous fluid flow. These systems usually record pressure in a unidirectional manner and may miss localized high-pressure events if the sensor alignment is suboptimal[36].

Solid-state catheters, by contrast, incorporate pressure sensors along the catheter shaft, enabling circumferential pressure measurement with faster response times and less susceptibility to artefacts. They simplify the procedure, reduce setup time and improve spatial resolution. Even though solid-state catheters provide superior resolution and operational efficiency, their increased rigidity and higher cost may reduce their tolerability in certain patients and limit widespread adoption. In terms of diagnostic output, both solid-state and water-perfused systems yield similar values for core metrics

such as IRP and DCI[35,36].

To improve the precision of catheter placement in complex anatomical scenarios, a newer approach integrates visual guidance at the time of probe insertion. Vision-enabled catheters incorporate an optical system at the distal tip, allowing direct visualization of the upper gastrointestinal tract. This innovation is particularly beneficial in patients with altered anatomy, such as large hiatal hernias or post-surgical changes, where traditional blind insertion may be challenging[37].

Following the technological and conceptual shift brought by HREM, the focus has now extended toward functional assessment tools that offer a more comprehensive view of esophageal performance[38]. These include ambulatory monitoring, HRIM, provocative testing, the FLIP, and emerging novel manometric metrics. Each of these modalities addresses diagnostic limitations of conventional HREM protocols and adds value in select clinical scenarios. Although HREM has largely replaced conventional perfused manometry in clinical practice due to its superior resolution and standardized protocols, ambulatory 24-hour esophageal manometry still plays a role in selected cases. It is particularly useful in patients with intermittent, posture- or meal-related symptoms that may not be reproduced during protocolized HREM testing[39]. In such cases, short test protocols based solely on standardized water swallows may fail to capture relevant motility abnormalities or establish a meaningful symptom correlation[40].

HRIM

To address these diagnostic blind spots, recent developments have expanded the methodological arsenal. HRIM, which integrates impedance sensors into the manometry catheter, enables the concurrent evaluation of pressure dynamics and bolus transit[41]. This dual approach is particularly valuable in identifying impaired esophageal clearance that may be overlooked when pressure data is interpreted in isolation. It also provides quantitative metrics that capture flow-related abnormalities, contributing to a more physiologically grounded analysis[42,43].

Two HRIM-derived parameters have gained increasing attention for their diagnostic relevance in recent clinical studies. The bolus flow time (BFT) reflects the duration of bolus transit through the EGJ an can detect outflow resistance even when IRP is within normal range[43]. Its calculation combines impedance and pressure data, and is based on detecting both the presence of a bolus—shown by a drop in impedance—and a pressure gradient that promotes normal (antegrade) flow across the EGJ[44]. Clinical studies have shown that BFT correlates with symptom severity and treatment response, particularly in achalasia patients, where it outperforms IRP in predicting symptomatic and radiographic outcomes post-treatment[45].

A second parameter, the Esophageal Impedance Integral (EII) ratio, complements BFT by quantifying bolus retention. It does so by comparing impedance values recorded during and after swallowing, thereby estimating the amount of residual intraluminal content[40]. The EII ratio has demonstrated a strong correlation with bolus retention observed on barium esophagram (fluoroscopic studies), supporting its role as a physiologically meaningful marker of ineffective esophageal clearance[40,46]. These metrics are particularly valuable in evaluating patients with IEM or non-obstructive dysphagia, where conventional pressure-based criteria may not fully explain persistent symptoms. Moreover, EII has been shown to discriminate between symptomatic patients and healthy controls, even in the absence of major motility disorders, reinforcing its potential diagnostic relevance in subtle esophageal dysfunction[47].

Despite their diagnostic potential and growing evidence base, neither BFT nor EII ratio has yet been incorporated into routine clinical interpretation or existing classification systems.

In cases where manometric findings are inconclusive or discordant with clinical symptoms, supplementary testing may be necessary to clarify the diagnosis. The TBE, offers a simple and objective method to assess esophageal emptying. Retention of barium, particularly column heights exceeding 5 cm at one minute or more than 2 cm at five minutes indicate impaired EGJ relaxation[48]. TBE is especially useful in the evaluation of achalasia and EGJOO, where it can confirm delayed bolus clearance and guide treatment decisions[49].

Provocative tests

Beyond standard single swallows, certain maneuvers have been integrated into manometric testing to uncover functional aspects of esophageal motility that may remain undetected otherwise. One such method is MRS which involves a sequence of five 2 mL water swallows delivered in rapid succession over fewer than 10 seconds. This stimulus induces transient inhibition of esophageal peristalsis and LES, followed by a contraction that provides insight about the esophageal peristaltic reserve[50]. The presence of an adequate response reflects intact neuromuscular coordination, while an absent or attenuated rebound suggests compromised function. When applied alongside conventional swallows, this test enhances the overall diagnostic yield of HREM in routine clinical practice[51,52].

A further extension of esophageal functional assessment is represented by the use of textured swallows, particularly solid or semi-solid test meals, which challenge the esophageal motor apparatus in a manner that more closely reflects real-life eating conditions[20,40,53]. Unlike the standard protocol based on repeated water swallows, textured boluses generate a distinct physiological response that can reveal subtle impairments not captured under routine conditions. Emerging data suggest that solid swallows evoke stronger contractile activity and higher outflow resistance across the EGJ, both of which may be masked during low-viscosity liquid swallows[53]. The inclusion of solid swallows in the HREM protocol has been associated with improved alignment between manometric findings and patient reported symptoms, particularly in cases with normal results during liquid testing. Disorders such as type III achalasia or EGJOO have been more frequently identified under these conditions, suggesting that solid boluses can reveal clinically relevant dysfunctions otherwise missed[54].

Preliminary thresholds suggest that having less than 20% of solid swallows with a DCI above 1000 mmHg·s·cm may indicate IEM, while IRP values exceeding 25 mmHg during solid swallows are suggestive of EGJOO[1]. However, normative values for solid swallows remain incompletely defined, and further studies are needed to standardize diagnostic criteria[53]. In addition, this approach has yet to be formally validated in large-scale prospective cohorts or

incorporated into current classification systems, and its clinical utility may be limited by procedural variability and patient tolerance.

Another technique proposed to enhance the diagnostic performance of manometry is the RDC, a provocative test designed to evaluate esophageal outflow resistance under conditions of sustained deglutitive inhibition[55]. In individuals with obstructive physiology, the test often induces characteristic findings such as PEP or elevated IRP[56]. When combined with HRIM, RDC allows evaluation of bolus clearance through impedance tracking. In asymptomatic subjects, clearance typically occurs rapidly, even in the absence of a visible peristaltic response, reflecting the contribution of LES relaxation and passive flow mechanism[57]. In contrast, patients with impaired EGJ relaxation frequently demonstrate persistent pressurization or delayed bolus transit following RDC, findings that may support a clinically meaningful diagnosis when conventional manometry is inconclusive[57]. Accordingly, RDC has proven particularly useful in reinforcing the diagnosis of type II achalasia or EGJOO in patients with borderline or equivocal findings on standard HREM protocols.

Ambulatory HREM manometry

Ambulatory manometry typically involves the transnasal placement of a catheter equipped with three pressure sensors, usually situated at 5 cm, 10 cm and 15 cm respectively from the LES. Following 24-hour measurements, the obtained data is analyzed regarding the patient's reported symptoms, mealtimes and bedtimes[58]. Building on this concept, Keller *et al* [59] implemented a high-resolution ambulatory manometry system using a 23-sensor catheter, allowing for detailed pressure mapping over a full day. Seventy-five patients with non-cardiac chest pain or non-obstructive dysphagia were evaluated using this method. Spastic or hypercontractile motility disorders were identified in 61.3% of cases, compared to only 21.3% during rice-meal HREM and 10.7% with standard water-swallow protocols ($P < 0.001$). These findings highlight the added diagnostic value of prolonged ambulatory monitoring in detecting clinically relevant motility abnormalities that are frequently missed by conventional stationary testing. When gastroesophageal reflux is associated with dysmotility, 24-hour pH or pH-impedance monitoring can be performed using a separate catheter, either alone or alongside manometric studies[60].

The use of ambulatory manometry is mostly important for but not limited to the investigation of esophageal motility disorders, particularly when combined with other diagnostic methods, such as pH monitoring, as well as potentially identifying subgroups of patients with normal stationary measurements[61-63]. Ambulatory monitoring was also useful in identifying esophageal spasm in patients with non-cardiac chest pain[39], with studies emphasizing its potential in pediatric populations as well, such as differentiating primary rumination from gastroesophageal reflux disease (GERD)-induced rumination and associating dysphagia and motor events in children with eosinophilic esophagitis and normal HREM measurements[64-66].

ADVANCES IN FUNCTIONAL ASSESSMENT - FLIP

Although not a manometric technique in the classical sense, FLIP provides dynamic pressure and distensibility measurements that complement HREM, particularly in evaluating EGJ outflow function and bolus accommodation[67]. FLIP is an improved pressure-measuring tool based on high-resolution impedance planimetry. Though it was introduced in 2009, it is currently only available in specialized centers. Its advantage lies in the fact that it allows the simultaneous quantification of two parameters: The luminal cross-sectional area along the esophagus and the intraluminal pressure. The ratio of these two measurements taken in the narrowest part of the esophagus constitutes the distensibility index (DI). This technique is commonly performed during upper endoscopy, using a fluid-distended balloon placed around a catheter with multiple impedance sensors for volumetric distension[68,69].

When used in conjunction with HREM, FLIP adds valuable information on the biomechanical properties of the esophageal wall and the functional opening characteristics of the EGJ. Rather than replacing manometry, it serves as a complementary tool, particularly useful in the diagnosis and follow-up of motility disorders such as GERD, achalasia, and EGJOO. FLIP is increasingly used during peroral endoscopic myotomy (POEM) to guide the extent of the esophageal and gastric myotomy by providing real-time EGJ distensibility measurements. Studies have shown that many patients reach optimal DI values (typically > 3 $mm^2/mmHg$) after a standard-length myotomy, suggesting that FLIP-guided tailoring could allow for shorter, more precise interventions. This approach may help achieve comparable symptomatic relief while potentially reducing the risk of postoperative GERD[70].

In treated achalasia, Jain *et al*[71] demonstrated that the EGJ - DI, measured using FLIP, is a significant predictor of treatment response. Importantly, this association is modulated by anatomic features of the EGJ, highlighting the need to interpret DI values in the context of structural findings. In eosinophilic esophagitis, characterized by fibrostenotic remodeling of esophageal wall, FLIP was efficient in assessing the risk of food impaction in correlation with the measured distensibility plateau[72]. In GERD, FLIP may help characterize the functional integrity of the EGJ by quantifying its distensibility. Increased DI values have been associated with impaired barrier function. Moreover, it proved useful in surgery guidance and monitoring. Studies reported its ability to facilitate decision-making when choosing which type of fundoplication is most appropriate in various cases of hiatal hernia repair and to identify post-procedural obstruction in patients complaining of dysphagia[73,74]. Pediatric patients above the age of 5 can also benefit from FLIP, especially in the monitoring of patients with esophageal atresia, while also reporting benefits in preventing post-esophagomyotomy reflux when used intraoperatively[75-77].

Esophageal monitoring generates a large amount of data and, consequently, its interpretation can be difficult and time consuming, with AI tools potentially addressing this aspect[78]. Jell *et al*[79] evaluated an AI-based instrument which can

automatically analyze patient swallows during 24-hour HREM testing. The results were promising, revealing accurate detection of approximately 98% of the swallows[79]. FLIP is another esophageal functional test in which AI demonstrated potential benefits. Kou *et al*[80] developed an AI model which facilitated the interpretation of this test, as it correctly placed 89% of the patients in the "normal" and "not normal" categories, respectively. Similar results were reported by Carlson *et al*[81], who used an AI-based model for FLIP data interpretation. This tool identified achalasia subtypes with 55% accuracy and correctly differentiated the spastic subtype from the non-spastic ones in 78% of the cases. Moreover, another study which assessed a probability tool used for EGJ obstruction identification in patients who had undergone HREM and FLIP demonstrated its efficiency in 89%-90% of cases[82].

AI IN ESOPHAGEAL MANOMETRY

AI tools have been explored in different areas of gastroenterology, including assisted endoscopy and treatment selection. When it comes to esophageal motility disorders, the interest in using AI has emerged more slowly, although machine learning (ML) models capable of diagnosing motility issues based on HREM interpretation have recently emerged, aiming to assist in pattern recognition and decision support in the evaluation of esophageal motility disorders[78,83,84].

AI refers to a broad set of computational methods that can mimic certain aspects of cognitive function, including classification, decision-making and adaptative learning. Among these, ML is commonly used in medical applications. ML includes both supervised learning algorithms, which learn from labeled data, and unsupervised approaches, which aim to uncover underlying patterns or clusters without predefined categories. In HREM analysis, supervised learning has been employed to train models that classify esophageal motility disorders according to the CC. In contrast, unsupervised learning has shown potential in identifying swallow patterns or physiological subtypes that may not be clearly defined within existing diagnostic frameworks[85]. Deep learning (DL), a subdomain of ML, is particularly suited to analyzing high-dimensional clinical data. Its layered neural network architectures cand extract hierarchical representations from input such as HREM images, impedance signals or time-series data. In esophageal motility, convolutional neural networks (CNN) have been used to analyze the spatial distribution of pressure across the esophagus during deglutition.

The application of AI in esophageal manometry reflects a broader transformation in medical diagnostics, where ML and DL are increasingly used not only to automate pattern recognition but also to model physiological processes. In esophageal motility assessment, traditional reliance on expert interpretation of HREM data has been gradually complemented by computational tools capable of quantifying underlying dynamics across the esophagus[8].

Initial research efforts emphasized the simulation of esophageal biomechanics through mathematical constructs, while subsequent studies expanded toward ML frameworks capable of extracting complex diagnostic patterns from HREM recordings. This multidimensional approach has contributed to a more refined understanding of esophageal motor function, offering tools that can either complement or enhance conventional diagnostic paradigms based on the CC.

Among the earliest strategies was the construction of biomechanical models intended to reproduce the mechanical activity of the esophagus during swallowing. A notable contribution in this domain comes from Carniel *et al*[86], who proposed a physiological modeling framework capable of simulating esophageal pressure distributions in both healthy and pathological states. Importantly, the authors applied their framework to a heterogeneous dataset including patients with achalasia types I-III, DES, jackhammer esophagus and EGJOO. Distinct parameters profiles emerged for each esophageal motility disorder. For instance, patients with achalasia type I demonstrated significantly diminished contraction amplitudes and delayed wave propagation, while those with DES showed more abrupt transitions in pressure along the distal esophagus. These distinctions suggest that physiological modeling could serve not only as a diagnostic adjunct but also as a mean to standardize and compress manometric data for future computational use.

A different study by Zifan *et al*[87], focused on patients with functional dysphagia, used impedance measurements to assess esophageal distension during bolus transit. Synchronized contraction-distension patterns from HREM recordings were extracted and ML further applied to distinguish affected individuals from healthy controls. This revealed that abnormalities in esophageal wall compliance, particularly during the distension phase, may serve as important physiological markers in patients whose contractile function appears normal on conventional manometric evaluation. These investigations illustrate how AI can be employed both to simulate physiological mechanisms and to extract diagnostic features from HREM data.

Building on these early efforts, Kou *et al*[88] explored a different use for AI applications by introducing unsupervised learning as a tool for discovering latent patterns in HREM recordings. In their study, the authors implemented a variational autoencoder (VAE), a neural network architecture designed to learn compressed, low-dimensional representations of complex input data without the need for diagnostic labels. The model was capable of portraying the multidimensional structure of HREM plots into a compact space that preserved essential physiological information, as well as classify swallows based on intrinsic properties[88]. This further led to a DL model which distinguished between normal peristalsis, compartmental pressurization, PEP and failed or premature contractions, offering potential utility in patients who do not meet clear diagnostic thresholds based on aggregate criteria[89]. To further integrate AI into clinical decision-making, Kou *et al*[78] proposed a multi-stage ML pipeline that mimics the hierarchical logic of the CC, with the model being able to replicate expert-level diagnostic behavior.

Beyond the efforts to classify motility disorders, recent studies have begun exploring how AI may refine the assessment of individual esophageal pressure dynamics. A study conducted by Jungheim *et al*[90] addressed the restitution time (RT) of the UES, a parameter representing the interval required for the sphincter to return from peak contraction to resting tone following deglutition. Authors implemented ML that utilized logistic regression and sequence labeling to automate the detection of the RT. The model was trained and validated on a dataset of HREM swallows from

healthy volunteers and was able to consistently approximate RT within the physiological range of 9-11 seconds[90].

Complementing this line of investigation, Rafieivand *et al*[91] proposed a fuzzy logic-based framework for diagnosing esophageal motility disorders using HREM data. Their model was designed to mimic the clinical reasoning process by interpreting pressure patterns through a series of expert defined fuzzy rules. Unlike conventional binary classifiers, this system permitted graded assessments of motility, accounting for the inherent uncertainty encountered in clinical datasets. The algorithm processed input features extracted from HREM studies, such as pressure amplitudes, propagation times and bolus transit markers. These were then mapped onto diagnostic outputs with varying degrees of confidence. The fuzzy system offers an alternative to DL models by enhancing interpretability and clinical transparency[91].

Further expanding the use of AI in the analysis of HREM images, Popa *et al*[92] used a DL CNN that directly processes topographic pressure images without requiring manual segmentation or parameter extraction. Their model was trained to distinguish esophageal motility disorders based on the visual features in HREM plots, recognizing pathological patterns based on swallow level identification. By relying solely on image-based input, this approach mimics the way clinicians visually interpret manometric tracings while eliminating interobserver variability and reducing the time required for diagnostic evaluation[93]. In a complementary contribution, Surdea-Blaga *et al*[94] proposed an AI model that replicates the stepwise logic of the CC v3.0, available at that time, through a decision tree algorithm applied to HREM images. The system employs a rule-based decision tree that sequentially analyzes HREM images, beginning with IRP assessment and progressing through diagnostic branches to reach a final categorization. Furthermore, the algorithm was trained to recognize typical swallow-related pressure morphologies and segmental pressurization profiles[94].

Unlike models primarily designed to deliver diagnostic outcomes, the framework introduced by Czako *et al*[95] emphasizes both clinical classification and procedural validation within HREM data. Their approach consists of a dual-module CNN that targets two essential elements: The evaluation of IRP and the detection of incorrect catheter positioning. The first component was trained to categorize IRP values as either within normal limits or abnormally elevated, thereby replicating the initial decision point in the CC. The second module was designed to verify probe positioning by analyzing the spatial organization of pressure zones. Aberrant or absent pressure transitions along the catheter length, often resulting from mispositioning, were recognized by the CNN. By integrating diagnostic and technical verification into a unified system, the model proposed by Czako *et al*[95] enhances data quality assurance and reinforces the reliability of subsequent diagnostic decisions.

While most applications of AI in HREM have focused on classification and pattern recognition, recent efforts suggest AI may also support the development and refinement of the diagnostic tools themselves. Popa *et al*[96] explored this concept by integrating Google's Gemini, a large language model, into the workflow for creating a DL model capable of classifying esophageal motility patterns on HREM images. In this study, the authors trained a CNN to distinguish between seven specific contractile patterns, including normal motility, premature, fragmented and failed swallows. Gemini was used throughout the development process, not to classify swallows directly, but to assist with data preprocessing, code generation, model tuning and interpretability. For instance, the implementation of LIME-based heatmaps to highlight relevant image regions was also optimized with Gemini's help[96]. The study highlights an alternative role for AI, not limited to diagnostic inference but extended to assist in the design, optimization and validation of the classification model itself.

In addition to classifying motility disorders and assisting in procedural validation, AI has also been applied to reconstructing esophageal motor function in a temporally structured manner. This perspective aligns more closely with the physiological continuity of deglutition and opens the way for individualized single-swallow motility profiles. A representative contribution in this direction comes from Wang *et al*[97], who proposed a DL framework capable of analyzing entire manometric studies as sequential motility functions. The system extracted consecutive swallows from HREM recordings and assembled them into a structured temporal sequence. These were then processed by a neural network architecture combining spatial convolution with recurrent layers, allowing the model to capture both localized contractile features and global motility dynamics. This approach supports not only classification but also the identification of evolving or transitional patterns that may elude conventional diagnostic thresholds[97].

The applicability of AI extends beyond diagnostic interpretation and into the operative field, where it may support procedural guidance, workflow optimization, and outcome prediction in esophageal surgery[98,99]. Recent studies in the context of POEM exemplify how AI can assist both intraoperative decision-making and patient stratification for tailored therapeutic strategies[100,101]. Ward *et al*[100] developed a DL model aimed at automatically identifying the operative phases of POEM surgery, achieving an overall accuracy of 87.6% in POEM videos. Additionally, the study concluded that the model performed best when analyzing longer operative phases[100]. Takahashi *et al*[101] developed several ML models trained on a large number of achalasia phenotypes (overall, a total number of 1824 patients with achalasia, among which 1778 underwent a POEM procedure) in order to predict the outcome of POEM in these patients. Additionally, by analyzing a significant number of HREM data, the models identified three achalasia phenotypes, namely pointing at possible different pathophysiology within the same HREM diagnosis. This was further extended to predicting the persistent symptoms, symptomatic patients for GERD, as well as reflux esophagitis after POEM. The best performing model achieved an area under the curve of 0.7 in predicting the persistence of symptoms after POEM, mainly encompassing the following variables: Age > 46 years, a pre-POEM Eckardt score > 6, IRP > 26, esophageal dilation grade 2, as well as the length of gastric myotomy of more than 2 cm[101].

Clinical relevance, educational applications, and future perspectives of AI in esophageal manometry

AI has the potential to enhance the diagnostic process in complex esophageal motility disorders by improving both accuracy and consistency. The interpretation of HREM remains subject to notable interobserver variability, and a key challenge lies in determining whether the identified motility abnormalities are clinically significant and require intervention. The most recent version of the CC (v4.0) addresses this need by shifting the focus from purely descriptive

manometric patterns to their clinical relevance. This is particularly important in conditions such as IEM and EGJOO, where the diagnostic label must reflect therapeutic implications. In line with this shift, CC4 incorporates clinical vignettes to anchor HREM findings within the broader clinical context, emphasizing the relationship between manometric patterns, patient symptoms, and therapeutic decision-making. This approach also helps avoid the overdiagnosis of manometric abnormalities that lack clinical significance. In this context, AI-based systems could provide integrative decision support by combining quantitative manometric data with clinical features, mirroring expert reasoning and enhancing diagnostic reproducibility across different levels of expertise and clinical environments. While numerous studies have already investigated the application of AI in HREM interpretation, future efforts should prioritize the incorporation of symptom profiles and complementary data from provocative maneuvers or adjunctive tests such as TBE or FLIP. Developing AI systems that integrate multiple data sources and clinical context is essential for making their use truly relevant in the diagnosis of esophageal motility disorders. This is also emphasized by Fass *et al*[8], who advocate for combining manometric data with patient presentation, demographics, and adjunctive tests such as FLIP or barium studies to ensure clinical applicability.

Beyond its role in diagnostic standardization, AI may also serve as a valuable tool in the education and training of clinicians performing esophageal manometry. By using expert-labeled datasets and interactive learning platforms, AI-based systems could provide real-time feedback, simulate diverse clinical scenarios, and offer explanations aligned with the principles of the CC. In addition to highlighting key features in HREM plots and adapting case complexity to the learner's level, these systems could be designed to integrate symptom patterns and ancillary test results—supporting not only technical skill acquisition but also the development of clinical reasoning. Such an approach would reduce reliance on expert supervision in early stages of training and promote a more consistent, context-aware interpretation of motility disorders among junior gastroenterologists[8,12].

The main features and applications of HREM (with the role of solid testing and ambulatory evaluation), as well as the role of FLIP and AI, are summarized in Table 1.

Table 1 Main features of current and novel techniques used in the evaluation of esophageal motility disorders

Technology		Features	Primary applications	Clinical impact/future role
FLIP		Measures EGJ distensibility and cross-sectional area	EGJ outflow evaluation, intraoperative guidance during POEM and fundoplication	Guides extent of myotomy or wrap; predicts treatment response[9]
Ambulatory HREM		24-hour, high-resolution pressure mapping with symptom correlation	Offers a better detection of clinically relevant abnormalities, with evaluation of posture- or meal-related symptoms	Has a higher diagnostic yield, especially in spastic or hypercontractile disorders, as well as in patients with non-cardiac chest pain, and non-obstructive dysphagia[102]
Novel catheters		Vision-enabled or solid-state catheters, improved sensor density	Easier placement, circumferential pressure measurement	Enhanced spatial resolution and patient comfort[37]
Solid swallows/test meals		Use of solid or semi-solid boluses during HREM	Detection of motility abnormalities by mimicking real-life eating conditions, improved symptom correlation	Adjunctive test important in borderline cases. Reveals EGJ outflow obstruction or type III achalasia not evident on liquid swallows[54]
AI analysis	Deep learning algorithms	Extracts hierarchical spatial and temporal features from manometric images or time-series data	Classifies motility patterns, identifies subtle or evolving abnormalities, supports temporal modeling of swallows	Enables end-to-end automated diagnosis; captures complex motility dynamics; reduces observer bias[88,89]
	Physiological modeling	Reproduces esophageal pressure dynamics and motility mechanisms	Models normal *vs* pathological motor activity; identifies disorder-specific mechanical profiles (*e.g.*, achalasia, DES, EGJOO)	Provides physiological insight, aids data compression and standardization for AI training, and helps refine diagnostic thresholds [86]
	Integrative & generative AI (LLMs)	Large language or multimodal models to optimize data processing, model development, and interpretability	Feature selection, code generation, and workflow automation; potential integration of HREM, FLIP, and clinical data	Facilitates explainability, enhances model transparency, and expands AI applications to education and system design[96]

AI: Artificial intelligence; HREM: High-resolution esophageal manometry; FLIP: Functional luminal imaging probe; EGJ: Esophagogastric junction; POEM: Peroral endoscopic myotomy; LLMs: Large language models; DES: Distal esophageal spasm; EGJOO: Esophagogastric junction outflow obstruction.

TRANSLATIONAL CHALLENGES AND INTEGRATION

Despite growing enthusiasm for AI in esophageal manometry, several barriers limit its transition into routine clinical use. Most current models are based on retrospective, single-center datasets that lack clinical diversity and standardized formatting, raising concerns about generalizability. Prospective, multicenter validation studies are essential to confirm that AI improves diagnostic accuracy, efficiency, and patient outcomes in real-world settings[4]. In addition, integration into existing clinical workflows requires technical compatibility with acquisition systems and electronic health records, as

well as intuitive interfaces for result interpretation and validation.

Clear protocols distinguishing AI-assisted from expert-led decisions, along with user training, will be necessary to support adoption. Regulatory frameworks must also be clarified, particularly regarding medical device classification, algorithm updates, and clinical liability in case of errors. Looking ahead, future developments may explore the use of AI for near real-time analysis of data obtained from ambulatory esophageal monitoring, such as prolonged manometry or impedance-pH studies. By correlating dynamic physiological recordings with symptom diaries or digital symptom-tracking tools, AI could help identify clinically meaningful motility patterns that fluctuate throughout the day[102].

CONCLUSION

Esophageal manometry has become a precise diagnostic method, supported by high-resolution tools and standardized classifications. Despite these advances, challenges remain in interpreting borderline findings, linking manometric data to symptoms, and integrating results across tests. Recent innovations—such as FLIP technology, ambulatory manometry, and advanced pressure metrics—offer the potential to improve both diagnostic accuracy and clinical relevance. AI has the potential to support multimodal integration in esophageal diagnostics—combining data from manometry, FLIP, impedance, imaging, and symptoms into a unified framework. Although still in early stages, AI may eventually enhance diagnostic precision and personalization. For clinical adoption, however, robust validation, regulatory approval, and transparent, user-friendly tools remain essential.

FOOTNOTES

Author contributions: Popa SL, Brata VD, and Surdea-Blaga T contributed to the conceptual design, supervision, and critical revision of the manuscript; Orășan OH, Chiarioni G, and Ismaiel A contributed to the literature search, critical revision, manuscript editing and interpretation of the content; Padureanu AM, Dumitrascu DI, Dita MO, Filip M, Duse TA, and Eftimie Spitz R contributed to manuscript writing and editing and provided critical intellectual input.

Conflict-of-interest statement: The authors declare no conflict of interest.

Open Access: This article is an open-access article that was selected by an in-house editor and fully peer-reviewed by external reviewers. It is distributed in accordance with the Creative Commons Attribution NonCommercial (CC BY-NC 4.0) license, which permits others to distribute, remix, adapt, build upon this work non-commercially, and license their derivative works on different terms, provided the original work is properly cited and the use is non-commercial. See: https://creativecommons.org/Licenses/by-nc/4.0/

Country of origin: Romania

ORCID number: Stefan Lucian Popa 0000-0002-5508-2598; Vlad Dumitru Brata 0000-0002-0007-8962; Olga Hilda Orășan 0000-0003-4435-142X; Giuseppe Chiarioni 0000-0002-9183-4750; Abdulrahman Ismaiel 0000-0001-7435-271X; Alexandru Marius Padureanu 0009-0009-2980-169X; Dinu Iuliu Dumitrascu 0000-0001-8042-1582; Miruna Oana Dita 0009-0001-1983-2793; Mara Filip 0009-0002-0149-7103; Traian Adrian Duse 0000-0002-5230-6680; Raphaël Eftimie Spitz 0009-0004-4338-6107; Teodora Surdea-Blaga 0000-0001-6020-4724.

S-Editor: Lin C
L-Editor: A
P-Editor: Wang WB

REFERENCES

1 **Fox MR**, Sweis R, Yadlapati R, Pandolfino J, Hani A, Defilippi C, Jan T, Rommel N. Chicago classification version 4.0(©) technical review: Update on standard high-resolution manometry protocol for the assessment of esophageal motility. *Neurogastroenterol Motil* 2021; **33**: e14120 [*RCA*] [PMID: 33729668 DOI: 10.1111/nmo.14120] [FullText]

2 **Rohof WOA**, Bredenoord AJ. Chicago Classification of Esophageal Motility Disorders: Lessons Learned. *Curr Gastroenterol Rep* 2017; **19**: 37 [*RCA*] [PMID: 28730503 DOI: 10.1007/s11894-017-0576-7] [FullText] [Full Text(PDF)]

3 **Hoshikawa Y**, Iwakiri K. Esophageal Motility Disorders: Diagnosis and Treatment Strategies. *Digestion* 2024; **105**: 11-17 [*RCA*] [PMID: 37634495 DOI: 10.1159/000533347] [FullText]

4 **Farah A**, Savarino EV, Abboud W, Tatakis A, Mari A. The Contemporary Diagnostic Approaches to Esophageal Symptomatology. *Cureus* 2025; **17**: e78804 [*RCA*] [PMID: 40078269 DOI: 10.7759/cureus.78804] [FullText] [Full Text(PDF)]

5 **Kahrilas PJ**, Ghosh SK, Pandolfino JE. Challenging the limits of esophageal manometry. *Gastroenterology* 2008; **134**: 16-18 [*RCA*] [PMID: 18166344 DOI: 10.1053/j.gastro.2007.11.031] [FullText] [Full Text(PDF)]

6 **Pandolfino JE**, Bulsiewicz WJ. Evaluation of esophageal motor disorders in the era of high-resolution manometry and intraluminal impedance. *Curr Gastroenterol Rep* 2009; **11**: 182-189 [*RCA*] [PMID: 19463217 DOI: 10.1007/s11894-009-0029-z] [FullText]

7 **Bredenoord AJ**, Smout AJ. High-resolution manometry. *Dig Liver Dis* 2008; **40**: 174-181 [*RCA*] [PMID: 18155652 DOI: 10.1016/j.dld.2007.11.006] [FullText]

8 **Fass O**, Rogers BD, Gyawali CP. Artificial Intelligence Tools for Improving Manometric Diagnosis of Esophageal Dysmotility. *Curr*

Gastroenterol Rep 2024; **26**: 115-123 [*RCA*] [PMID: 38324172 DOI: 10.1007/s11894-024-00921-z] [FullText]

9 **Fass OZ**, Carlson DA. Functional Lumen Imaging Probe Panometry. *Gastrointest Endosc Clin N Am* 2025; **35**: 571-585 [*RCA*] [PMID: 40412991 DOI: 10.1016/j.giec.2025.01.007] [FullText]

10 **Clouse RE**, Staiano A, Alrakawi A, Haroian L. Application of topographical methods to clinical esophageal manometry. *Am J Gastroenterol* 2000; **95**: 2720-2730 [*RCA*] [PMID: 11051340 DOI: 10.1111/j.1572-0241.2000.03178.x] [FullText]

11 **Kahrilas PJ**, Nguyen NT. The Esophagogastric Junction Reconsidered. *Gastrointest Endosc Clin N Am* 2025; **35**: 541-553 [*RCA*] [PMID: 40412989 DOI: 10.1016/j.giec.2025.01.003] [FullText]

12 **Akimoto S**, Singhal S, Masuda T, Mittal SK. Classification for esophagogastric junction (EGJ) complex based on physiology. *Dis Esophagus* 2017; **30**: 1-6 [*RCA*] [PMID: 30052824 DOI: 10.1093/dote/dox048] [FullText]

13 **Farah A**, Abboud W, Savarino EV, Mari A. Esophageal Intelligence: Implementing Artificial Intelligence Into the Diagnostics of Esophageal Motility and Impedance pH Monitoring. *Neurogastroenterol Motil* 2025; **37**: e70038 [*RCA*] [PMID: 40145475 DOI: 10.1111/nmo.70038] [Full Text]

14 **Magendie F**. Pris entaire de physiologie. Paris: Chez Muignon-Marvis, 1825 [DOI: 10.5962/bhl.title.43397] [FullText]

15 **Kronecker H**, Meltzer S. Der Schluckmechanismus, seine Erregung und seine Hemmung. In: Physiologische Gesellschaft zu Berlin. [cited 27 August 2025]. Available from: https://www.biodiversitylibrary.org/page/35375544#page/342/mode/1up

16 **Hightower NC Jr**. Swallowing and esophageal motility. *Am J Dig Dis* 1958; **3**: 562-583 [*RCA*] [PMID: 13559196 DOI: 10.1007/BF02231242] [FullText]

17 **Millhon WA**, Hoffman DE, Jarvis P, Cross CJ, Millhon JS, Crites NA. Preliminary report on Millhon-Crites intraesophageal motility probe. *Am J Dig Dis* 1968; **13**: 929-933 [*RCA*] [PMID: 5680905 DOI: 10.1007/BF02237580] [FullText]

18 **Arndorfer RC**, Stef JJ, Dodds WJ, Linehan JH, Hogan WJ. Improved infusion system for intraluminal esophageal manometry. *Gastroenterology* 1977; **73**: 23-27 [PMID: 324861 DOI: 10.1016/S0016-5085(19)32264-4] [FullText]

19 **Kahrilas PJ**, Ghosh SK, Pandolfino JE. Esophageal motility disorders in terms of pressure topography: the Chicago Classification. *J Clin Gastroenterol* 2008; **42**: 627-635 [*RCA*] [PMID: 18364587 DOI: 10.1097/MCG.0b013e31815ea291] [FullText] [Full Text(PDF)]

20 **Yadlapati R**, Kahrilas PJ, Fox MR, Bredenoord AJ, Prakash Gyawali C, Roman S, Babaei A, Mittal RK, Rommel N, Savarino E, Sifrim D, Smout A, Vaezi MF, Zerbib F, Akiyama J, Bhatia S, Bor S, Carlson DA, Chen JW, Cisternas D, Cock C, Coss-Adame E, de Bortoli N, Defilippi C, Fass R, Ghoshal UC, Gonlachanvit S, Hani A, Hebbard GS, Wook Jung K, Katz P, Katzka DA, Khan A, Kohn GP, Lazarescu A, Lengliner J, Mittal SK, Omari T, Park MI, Penagini R, Pohl D, Richter JE, Serra J, Sweis R, Tack J, Tatum RP, Tutuian R, Vela MF, Wong RK, Wu JC, Xiao Y, Pandolfino JE. Esophageal motility disorders on high-resolution manometry: Chicago classification version 4.0(©). *Neurogastroenterol Motil* 2021; **33**: e14058 [*RCA*] [PMID: 33373111 DOI: 10.1111/nmo.14058] [FullText]

21 **Bredenoord AJ**, Tutuian R, Smout AJ, Castell DO. Technology review: Esophageal impedance monitoring. *Am J Gastroenterol* 2007; **102**: 187-194 [*RCA*] [PMID: 17100961 DOI: 10.1111/j.1572-0241.2006.00966.x] [FullText]

22 **Dhawan I**, O'Connell B, Patel A, Schey R, Parkman HP, Friedenberg F. Utility of Esophageal High-Resolution Manometry in Clinical Practice: First, Do HRM. *Dig Dis Sci* 2018; **63**: 3178-3186 [*RCA*] [PMID: 30276571 DOI: 10.1007/s10620-018-5300-4] [FullText]

23 **van Hoeij FB**, Bredenoord AJ. Clinical Application of Esophageal High-resolution Manometry in the Diagnosis of Esophageal Motility Disorders. *J Neurogastroenterol Motil* 2016; **22**: 6-13 [*RCA*] [PMID: 26631942 DOI: 10.5056/jnm15177] [FullText] [Full Text(PDF)]

24 **Tack J**, Pauwels A, Roman S, Savarino E, Smout A; ESNM HRM consensus group. European Society for Neurogastroenterology and Motility (ESNM) recommendations for the use of high-resolution manometry of the esophagus. *Neurogastroenterol Motil* 2021; **33**: e14043 [*RCA*] [PMID: 33274525 DOI: 10.1111/nmo.14043] [FullText]

25 **Patel DA**, Yadlapati R, Vaezi MF. Esophageal Motility Disorders: Current Approach to Diagnostics and Therapeutics. *Gastroenterology* 2022; **162**: 1617-1634 [*RCA*] [PMID: 35227779 DOI: 10.1053/j.gastro.2021.12.289] [FullText]

26 **Clouse RE**, Staiano A. Topography of the esophageal peristaltic pressure wave. *Am J Physiol* 1991; **261**: G677-G684 [*RCA*] [PMID: 1928353 DOI: 10.1152/ajpgi.1991.261.4.G677] [FullText]

27 **Carlson DA**, Pandolfino JE. High-Resolution Manometry in Clinical Practice. *Gastroenterol Hepatol (N Y)* 2015; **11**: 374-384 [*RCA*] [PMID: 27118931] [FullText]

28 **Vasireddy AR**, Leggett CL, Kamboj AK. Esophageal Motility Disorders: A Concise Review on Classification, Diagnosis, and Management. *Mayo Clin Proc* 2025; **100**: 332-339 [*RCA*] [PMID: 39909671 DOI: 10.1016/j.mayocp.2024.09.024] [FullText]

29 **Gyawali CP**, Zerbib F, Bhatia S, Cisternas D, Coss-Adame E, Lazarescu A, Pohl D, Yadlapati R, Penagini R, Pandolfino J. Chicago Classification update (V4.0): Technical review on diagnostic criteria for ineffective esophageal motility and absent contractility. *Neurogastroenterol Motil* 2021; **33**: e14134 [*RCA*] [PMID: 33768698 DOI: 10.1111/nmo.14134] [FullText]

30 **Zaninotto G**, Bennett C, Boeckxstaens G, Costantini M, Ferguson MK, Pandolfino JE, Patti MG, Ribeiro U Jr, Richter J, Swanstrom L, Tack J, Triadafilopoulos G, Markar SR, Salvador R, Faccio L, Andreollo NA, Cecconello I, Costamagna G, da Rocha JRM, Hungness ES, Fisichella PM, Fuchs KH, Gockel I, Gurski R, Gyawali CP, Herbella FAM, Holloway RH, Hongo M, Jobe BA, Kahrilas PJ, Katzka DA, Dua KS, Liu D, Moonen A, Nasi A, Pasricha PJ, Penagini R, Perretta S, Sallum RAA, Sarnelli G, Savarino E, Schlottmann F, Sifrim D, Soper N, Tatum RP, Vaezi MF, van Herwaarden-Lindeboom M, Vanuytsel T, Vela MF, Watson DI, Zerbib F, Gittens S, Pontillo C, Vermigli S, Inama D, Low DE. The 2018 ISDE achalasia guidelines. *Dis Esophagus* 2018; **31** [*RCA*] [PMID: 30169645 DOI: 10.1093/dote/doy071] [FullText]

31 **Philonenko S**, Roman S, Zerbib F, Gourcerol G, Gault N, Ropert A, Bruley des Varannes S, Barret M, Vitton V, Bouchoucha M, Billard N, Gorbatchef C, Duboc H, Coffin B. Jackhammer esophagus: Clinical presentation, manometric diagnosis, and therapeutic results-Results from a multicenter French cohort. *Neurogastroenterol Motil* 2020; **32**: e13918 [*RCA*] [PMID: 32510747 DOI: 10.1111/nmo.13918] [FullText]

32 **Triadafilopoulos G**, Tandon A, Shetler KP, Clarke J. Clinical and pH study characteristics in reflux patients with and without ineffective oesophageal motility (IEM). *BMJ Open Gastroenterol* 2016; **3**: e000126 [*RCA*] [PMID: 28074151 DOI: 10.1136/bmjgast-2016-000126] [Full Text] [Full Text(PDF)]

33 **Schupack D**, Katzka DA, Geno DM, Ravi K. The clinical significance of esophagogastric junction outflow obstruction and hypercontractile esophagus in high resolution esophageal manometry. *Neurogastroenterol Motil* 2017; **29**: 1-9 [*RCA*] [PMID: 28544670 DOI: 10.1111/nmo.13105] [FullText]

34 **Pandolfino JE**, Roman S, Carlson D, Luger D, Bidari K, Boris L, Kwiatek MA, Kahrilas PJ. Distal esophageal spasm in high-resolution esophageal pressure topography: defining clinical phenotypes. *Gastroenterology* 2011; **141**: 469-475 [*RCA*] [PMID: 21679709 DOI: 10.1053/j.gastro.2011.04.058] [FullText]

35 **Latorre-Rodríguez AR**, Mittal SK. Brief guidelines for beginners on how to perform and analyze esophageal high-resolution manometry.

Gastroenterol Hepatol 2024; **47**: 661-671 [*RCA*] [PMID: 38266818 DOI: 10.1016/j.gastrohep.2024.01.003] [FullText]
36 **Wang K**, Duan LP, Ge Y, Xia ZW, Xu ZJ. A comparative study of 22-channel water-perfusion system and solid-state system with 36-sensors in esophageal manometery. *BMC Gastroenterol* 2012; **12**: 157 [*RCA*] [PMID: 23134719 DOI: 10.1186/1471-230X-12-157] [FullText] [Full Text(PDF)]
37 **Kim HM**. Development of a Vision-assisted Manometry Catheter for High-resolution Esophageal Manometry. *J Neurogastroenterol Motil* 2016; **22**: 149-152 [*RCA*] [PMID: 26350939 DOI: 10.5056/jnm15049] [FullText] [Full Text(PDF)]
38 **Gyawali CP**, Penagini R. Clinical usefulness of esophageal high resolution manometry and adjunctive tests: An update. *Dig Liver Dis* 2021; **53**: 1373-1380 [*RCA*] [PMID: 33994122 DOI: 10.1016/j.dld.2021.04.007] [FullText]
39 **Barret M**, Herregods TV, Oors JM, Smout AJ, Bredenoord AJ. Diagnostic yield of 24-hour esophageal manometry in non-cardiac chest pain. *Neurogastroenterol Motil* 2016; **28**: 1186-1193 [*RCA*] [PMID: 27018150 DOI: 10.1111/nmo.12818] [FullText]
40 **Yadlapati R**, Furuta GT, Menard-Katcher P. New Developments in Esophageal Motility Testing. *Curr Treat Options Gastroenterol* 2019; **17**: 76-88 [*RCA*] [PMID: 30712156 DOI: 10.1007/s11938-019-00218-5] [FullText]
41 **Patel A**, Gyawali CP. How to Optimally Apply Impedance in the Evaluation of Esophageal Dysmotility. *Curr Gastroenterol Rep* 2016; **18**: 60 [*RCA*] [PMID: 27738965 DOI: 10.1007/s11894-016-0534-9] [FullText]
42 **Lin Z**, Nicodème F, Lin CY, Mogni B, Friesen L, Kahrilas PJ, Pandolfino JE. Parameters for quantifying bolus retention with high-resolution impedance manometry. *Neurogastroenterol Motil* 2014; **26**: 929-936 [*RCA*] [PMID: 24750336 DOI: 10.1111/nmo.12346] [FullText]
43 **Lin Z**, Yim B, Gawron A, Imam H, Kahrilas PJ, Pandolfino JE. The four phases of esophageal bolus transit defined by high-resolution impedance manometry and fluoroscopy. *Am J Physiol Gastrointest Liver Physiol* 2014; **307**: G437-G444 [*RCA*] [PMID: 24970774 DOI: 10.1152/ajpgi.00148.2014] [FullText]
44 **Carlson DA**, Lin Z, Kahrilas PJ, Sternbach J, Hungness ES, Soper NJ, Balla M, Listernick Z, Tye M, Ritter K, Craft J, Ciolino JD, Pandolfino JE. High-Resolution Impedance Manometry Metrics of the Esophagogastric Junction for the Assessment of Treatment Response in Achalasia. *Am J Gastroenterol* 2016; **111**: 1702-1710 [*RCA*] [PMID: 27698386 DOI: 10.1038/ajg.2016.442] [FullText]
45 **Ghosh SK**, Kahrilas PJ, Lodhia N, Pandolfino JE. Utilizing intraluminal pressure differences to predict esophageal bolus flow dynamics. *Am J Physiol Gastrointest Liver Physiol* 2007; **293**: G1023-G1028 [*RCA*] [PMID: 17855763 DOI: 10.1152/ajpgi.00384.2007] [FullText]
46 **Carlson DA**, Omari T, Lin Z, Rommel N, Starkey K, Kahrilas PJ, Tack J, Pandolfino JE. High-resolution impedance manometry parameters enhance the esophageal motility evaluation in non-obstructive dysphagia patients without a major Chicago Classification motility disorder. *Neurogastroenterol Motil* 2017; **29** [*RCA*] [PMID: 27647522 DOI: 10.1111/nmo.12941] [FullText]
47 **Carlson DA**, Lin Z, Kou W, Pandolfino JE. Inter-rater agreement of novel high-resolution impedance manometry metrics: Bolus flow time and esophageal impedance integral ratio. *Neurogastroenterol Motil* 2018; **30**: e13289 [*RCA*] [PMID: 29322591 DOI: 10.1111/nmo.13289] [Full Text]
48 **Blonski W**, Kumar A, Feldman J, Richter JE. Timed barium swallow for assessing long-term treatment response in patients with achalasia: Absolute cutoff versus percent change - A cross-sectional analytic study. *Neurogastroenterol Motil* 2021; **33**: e14005 [*RCA*] [PMID: 32996266 DOI: 10.1111/nmo.14005] [FullText]
49 **Fass OZ**, Pandolfino JE, Schauer JM, Ganesh N, Farina DA, Lat A, Goudie E, Kelahan LC, Carlson DA. Diagnostic Accuracy of Timed Barium Esophagram for Achalasia. *Gastroenterology* 2025; **169**: 63-72 [*RCA*] [PMID: 40020937 DOI: 10.1053/j.gastro.2025.02.013] [Full Text]
50 **Shaker A**, Stoikes N, Drapekin J, Kushnir V, Brunt LM, Gyawali CP. Multiple rapid swallow responses during esophageal high-resolution manometry reflect esophageal body peristaltic reserve. *Am J Gastroenterol* 2013; **108**: 1706-1712 [*RCA*] [PMID: 24019081 DOI: 10.1038/ajg.2013.289] [FullText]
51 **Herregods TV**, Roman S, Kahrilas PJ, Smout AJ, Bredenoord AJ. Normative values in esophageal high-resolution manometry. *Neurogastroenterol Motil* 2015; **27**: 175-187 [*RCA*] [PMID: 25545201 DOI: 10.1111/nmo.12500] [FullText]
52 **Mauro A**, Savarino E, De Bortoli N, Tolone S, Pugliese D, Franchina M, Gyawali CP, Penagini R. Optimal number of multiple rapid swallows needed during high-resolution esophageal manometry for accurate prediction of contraction reserve. *Neurogastroenterol Motil* 2018; **30**: e13253 [*RCA*] [PMID: 29159898 DOI: 10.1111/nmo.13253] [FullText]
53 **Sweis R**, Anggiansah A, Wong T, Kaufman E, Obrecht S, Fox M. Normative values and inter-observer agreement for liquid and solid bolus swallows in upright and supine positions as assessed by esophageal high-resolution manometry. *Neurogastroenterol Motil* 2011; **23**: 509-e198 [*RCA*] [PMID: 21342362 DOI: 10.1111/j.1365-2982.2011.01682.x] [FullText]
54 **Ang D**, Misselwitz B, Hollenstein M, Knowles K, Wright J, Tucker E, Sweis R, Fox M. Diagnostic yield of high-resolution manometry with a solid test meal for clinically relevant, symptomatic oesophageal motility disorders: serial diagnostic study. *Lancet Gastroenterol Hepatol* 2017; **2**: 654-661 [*RCA*] [PMID: 28684262 DOI: 10.1016/S2468-1253(17)30148-6] [FullText]
55 **Woodland P**, Gabieta-Sonmez S, Arguero J, Ooi J, Nakagawa K, Glasinovic E, Yazaki E, Sifrim D. 200 mL Rapid Drink Challenge During High-resolution Manometry Best Predicts Objective Esophagogastric Junction Obstruction and Correlates With Symptom Severity. *J Neurogastroenterol Motil* 2018; **24**: 410-414 [*RCA*] [PMID: 29969859 DOI: 10.5056/jnm18038] [FullText] [Full Text(PDF)]
56 **Marin I**, Serra J. Patterns of esophageal pressure responses to a rapid drink challenge test in patients with esophageal motility disorders. *Neurogastroenterol Motil* 2016; **28**: 543-553 [*RCA*] [PMID: 26686375 DOI: 10.1111/nmo.12749] [FullText]
57 **Marin I**, Cisternas D, Abrao L, Lemme E, Bilder C, Ditaranto A, Coello R, Hani A, Leguizamo AM, Meixueiro A, Remes-Troche J, Zavala MA, Ruiz de León A, Perez de la Serna J, Valdovinos MA, Serra J. Normal values of esophageal pressure responses to a rapid drink challenge test in healthy subjects: results of a multicenter study. *Neurogastroenterol Motil* 2017; **29** [*RCA*] [PMID: 28133879 DOI: 10.1111/nmo.13021] [FullText]
58 **Kamal AN**, Clarke JO, Oors JM, Bredenoord AJ. The role of ambulatory 24-hour esophageal manometry in clinical practice. *Neurogastroenterol Motil* 2020; **32**: e13861 [*RCA*] [PMID: 32391594 DOI: 10.1111/nmo.13861] [FullText] [Full Text(PDF)]
59 **Keller J**, Boedler M, Jasper D, Andresen V, Rosien U, Rösch T, Layer P. Additional Diagnostic Yield of Ambulatory 24-h High Resolution Manometry With Impedance in Patients With Non-Cardiac Chest Pain or Non-Obstructive Dysphagia. *Neurogastroenterol Motil* 2025; **37**: e70048 [*RCA*] [PMID: 40228103 DOI: 10.1111/nmo.70048] [FullText] [Full Text(PDF)]
60 **Babbar S**, Omara M, Khan A, Knotts R. Manometric esophagogastric junction barrier metrics as predictors of gastroesophageal reflux. *Esophagus* 2024; **21**: 397-404 [*RCA*] [PMID: 38691207 DOI: 10.1007/s10388-024-01057-9] [FullText]
61 **Paterson WG**, Murat BW. Combined ambulatory esophageal manometry and dual-probe pH-metry in evaluation of patients with chronic unexplained cough. *Dig Dis Sci* 1994; **39**: 1117-1125 [*RCA*] [PMID: 8174426 DOI: 10.1007/BF02087567] [FullText]

62 **Chrysos E**, Athanasakis E, Zoras OJ, Tsiaoussis J, Xynos E. Twenty-four-hour ambulatory versus stationary esophageal manometry in the evaluation of esophageal motility in patients with gastroesophageal reflux disease. *Digestion* 2002; **66**: 1-8 [*RCA*] [PMID: 12379808 DOI: 10.1159/000064422] [FullText]

63 **Pandolfino JE**, Richter JE, Ours T, Guardino JM, Chapman J, Kahrilas PJ. Ambulatory esophageal pH monitoring using a wireless system. *Am J Gastroenterol* 2003; **98**: 740-749 [*RCA*] [PMID: 12738450 DOI: 10.1111/j.1572-0241.2003.07398.x] [FullText]

64 **van Lennep M**, Leijdekkers ML, Oors JM, Benninga MA, van Wijk MP, Singendonk MMJ. Clinical Experience With Performing Esophageal Function Testing in Children. *J Pediatr Gastroenterol Nutr* 2021; **72**: 226-231 [*RCA*] [PMID: 33230070 DOI: 10.1097/MPG.0000000000003000] [FullText] [Full Text(PDF)]

65 **Singendonk MMJ**, Oors JM, Bredenoord AJ, Omari TI, van der Pol RJ, Smits MJ, Benninga MA, van Wijk MP. Objectively diagnosing rumination syndrome in children using esophageal pH-impedance and manometry. *Neurogastroenterol Motil* 2017; **29** [*RCA*] [PMID: 28078818 DOI: 10.1111/nmo.12996] [FullText]

66 **Nurko S**, Rosen R. Esophageal dysmotility in patients who have eosinophilic esophagitis. *Gastrointest Endosc Clin N Am* 2008; **18**: 73-89 [*RCA*] [PMID: 18061103 DOI: 10.1016/j.giec.2007.09.006] [FullText] [Full Text(PDF)]

67 **Carlson DA**, Pandolfino JE, Yadlapati R, Vela MF, Spechler SJ, Schnoll-Sussman FH, Lynch K, Lazarescu A, Khan A, Katz P, Jain AS, Gyawali CP, Gupta M, Garza JM, Fass R, Clarke JO, Chokshi RV, Chen J, Ravi K, Chan WW, Sultan S, Konda VJA. A Standardized Approach to Performing and Interpreting Functional Lumen Imaging Probe Panometry for Esophageal Motility Disorders: The Dallas Consensus. *Gastroenterology* 2025; **168**: 1114-1127.e5 [*RCA*] [PMID: 39914779 DOI: 10.1053/j.gastro.2025.01.234] [FullText] [Full Text (PDF)]

68 **Hirano I**, Pandolfino JE, Boeckxstaens GE. Functional Lumen Imaging Probe for the Management of Esophageal Disorders: Expert Review From the Clinical Practice Updates Committee of the AGA Institute. *Clin Gastroenterol Hepatol* 2017; **15**: 325-334 [*RCA*] [PMID: 28212976 DOI: 10.1016/j.cgh.2016.10.022] [FullText]

69 **Chen HM**, Li BW, Li LY, Xia L, Chen XB, Shah R, Abdelfatah MM, Jain A, Cassani L, Massaad J, Keilin S, Cai Q. Functional lumen imaging probe in gastrointestinal motility diseases. *J Dig Dis* 2019; **20**: 572-577 [*RCA*] [PMID: 31498966 DOI: 10.1111/1751-2980.12818] [FullText]

70 **Kara AM**, Haas AJ, Alkhatib H, DeCicco J, Semanate RC, Kim HKJ, Prasad R, Bardaro S, Dorsey A, El-Hayek K. Esophageal impedance planimetry during per-oral endoscopic myotomy guides myotomy extent. *Surg Endosc* 2024; **38**: 5377-5384 [*RCA*] [PMID: 39043885 DOI: 10.1007/s00464-024-11067-4] [FullText] [Full Text(PDF)]

71 **Jain AS**, Carlson DA, Triggs J, Tye M, Kou W, Campagna R, Hungness E, Kim D, Kahrilas PJ, Pandolfino JE. Esophagogastric Junction Distensibility on Functional Lumen Imaging Probe Topography Predicts Treatment Response in Achalasia-Anatomy Matters! *Am J Gastroenterol* 2019; **114**: 1455-1463 [*RCA*] [PMID: 30741739 DOI: 10.14309/ajg.0000000000000137] [FullText]

72 **Moosavi S**, Shehata C, Kou W, Hirano I, Gonsalves N, Peterson S, Pandolfino JE, Carlson DA. Measuring esophageal compliance using functional lumen imaging probe to assess remodeling in eosinophilic esophagitis. *Neurogastroenterol Motil* 2023; **35**: e14525 [*RCA*] [PMID: 36600494 DOI: 10.1111/nmo.14525] [FullText]

73 **Alkhatib H**, Haas AJ, Kara AM, Lai C, Feria A, Bardaro S, Dorsey A, El-Hayek K. Tailoring the wrap: intraoperative functional lumen imaging probe (FLIP) during hiatal hernia repair. *Surg Endosc* 2024; **38**: 3425-3432 [*RCA*] [PMID: 38722379 DOI: 10.1007/s00464-024-10851-6] [FullText]

74 **Samo S**, Mulki R, Godiers ML, Obineme CG, Calderon LF, Bloch JM, Kim JJ, Shahnavaz N, Raja SM, Patnana SV, Willingham FF, Keilin SA, Cai Q, Christie JA, Srinivasan S, Lin E, Davis SS Jr, Jain AS. Utilizing functional lumen imaging probe in directing treatment for post-fundoplication dysphagia. *Surg Endosc* 2021; **35**: 4418-4426 [*RCA*] [PMID: 32880014 DOI: 10.1007/s00464-020-07941-6] [FullText]

75 **Hoskins B**, Almazan E, Mogul D, Ng K. Endoluminal Functional Lumen Imaging Probe Is Safe in Children Under Five Years Old. *J Pediatr Gastroenterol Nutr* 2022; **74**: e148-e152 [*RCA*] [PMID: 35849505 DOI: 10.1097/MPG.0000000000003430] [FullText]

76 **Destro F**, Costanzo S, Durante E, Carcassola MS, Meroni M, Brunero M, Riccio A, Calcaterra V, Pelizzo G. Utility of Functional Lumen Imaging Probe in Long-Term Follow-Up of Children with Esophageal Atresia: A Single-Center Retrospective Study. *Children (Basel)* 2022; **9**: 1426 [*RCA*] [PMID: 36291362 DOI: 10.3390/children9101426] [FullText] [Full Text(PDF)]

77 **Howk AA**, Clifton MS, Garza JM, Durham MM. Impedance planimetry (EndoFLIP) assisted laparoscopic esophagomyotomy in pediatric population. *J Pediatr Surg* 2022; **57**: 1000-1004 [*RCA*] [PMID: 35659759 DOI: 10.1016/j.jpedsurg.2022.05.004] [FullText]

78 **Kou W**, Carlson DA, Baumann AJ, Donnan EN, Schauer JM, Etemadi M, Pandolfino JE. A multi-stage machine learning model for diagnosis of esophageal manometry. *Artif Intell Med* 2022; **124**: 102233 [*RCA*] [PMID: 35115131 DOI: 10.1016/j.artmed.2021.102233] [FullText]

79 **Jell A**, Kuttler C, Ostler D, Hüser N. How to Cope with Big Data in Functional Analysis of the Esophagus. *Visc Med* 2020; **36**: 439-442 [*RCA*] [PMID: 33447599 DOI: 10.1159/000511931] [FullText]

80 **Kou W**, Soni P, Klug MW, Etemadi M, Kahrilas PJ, Pandolfino JE, Carlson DA. An artificial intelligence platform provides an accurate interpretation of esophageal motility from Functional Lumen Imaging Probe Panometry studies. *Neurogastroenterol Motil* 2023; **35**: e14549 [*RCA*] [PMID: 36808777 DOI: 10.1111/nmo.14549] [FullText] [Full Text(PDF)]

81 **Carlson DA**, Kou W, Rooney KP, Baumann AJ, Donnan E, Triggs JR, Teitelbaum EN, Holmstrom A, Hungness E, Sethi S, Kahrilas PJ, Pandolfino JE. Achalasia subtypes can be identified with functional luminal imaging probe (FLIP) panometry using a supervised machine learning process. *Neurogastroenterol Motil* 2021; **33**: e13932 [*RCA*] [PMID: 32608147 DOI: 10.1111/nmo.13932] [FullText]

82 **Schauer JM**, Kou W, Prescott JE, Kahrilas PJ, Pandolfino JE, Carlson DA. Estimating Probability for Esophageal Obstruction: A Diagnostic Decision Support Tool Applying Machine Learning to Functional Lumen Imaging Probe Panometry. *J Neurogastroenterol Motil* 2022; **28**: 572-579 [*RCA*] [PMID: 36250364 DOI: 10.5056/jnm21239] [FullText] [Full Text(PDF)]

83 **Alowais SA**, Alghamdi SS, Alsuhebany N, Alqahtani T, Alshaya AI, Almohareb SN, Aldairem A, Alrashed M, Bin Saleh K, Badreldin HA, Al Yami MS, Al Harbi S, Albekairy AM. Revolutionizing healthcare: the role of artificial intelligence in clinical practice. *BMC Med Educ* 2023; **23**: 689 [*RCA*] [PMID: 37740191 DOI: 10.1186/s12909-023-04698-z] [FullText] [Full Text(PDF)]

84 **Mascarenhas M**, Mota J, Cordeiro JR, Mendes F, Martins M, Cardoso P, Almeida MJ, Pinto da Costa A, Martinez IH, Royo VM, Niland B, Di Palma J, Ferreira J, Macedo G, Santander C. Artificial Intelligence Driven Diagnosis of Motility Patterns in High-Resolution Esophageal Manometry - A Multicentric Multidevice Study. *Clin Transl Gastroenterol* 2025 [*RCA*] [PMID: 41128763 DOI: 10.14309/ctg.0000000000000941] [FullText]

85 **Bajwa J**, Munir U, Nori A, Williams B. Artificial intelligence in healthcare: transforming the practice of medicine. *Future Healthc J* 2021; **8**: e188-e194 [*RCA*] [PMID: 34286183 DOI: 10.7861/fhj.2021-0095] [FullText]

86 **Carniel EL**, Frigo A, Costantini M, Giuliani T, Nicoletti L, Merigliano S, Natali AN. A physiological model for the investigation of esophageal motility in healthy and pathologic conditions. *Proc Inst Mech Eng H* 2016; **230**: 892-899 [*RCA*] [PMID: 27422826 DOI: 10.1177/0954411916658915] [FullText]

87 **Zifan A**, Lin J, Peng Z, Bo Y, Mittal RK. Unraveling Functional Dysphagia: A Game-Changing Automated Machine-Learning Diagnostic Approach. *Appl Sci* 2023; **13**: 10116 [DOI: 10.3390/app131810116] [FullText]

88 **Kou W**, Carlson DA, Baumann AJ, Donnan E, Luo Y, Pandolfino JE, Etemadi M. A deep-learning-based unsupervised model on esophageal manometry using variational autoencoder. *Artif Intell Med* 2021; **112**: 102006 [*RCA*] [PMID: 33581826 DOI: 10.1016/j.artmed.2020.102006] [FullText]

89 **Kou W**, Galal GO, Klug MW, Mukhin V, Carlson DA, Etemadi M, Kahrilas PJ, Pandolfino JE. Deep learning-based artificial intelligence model for identifying swallow types in esophageal high-resolution manometry. *Neurogastroenterol Motil* 2022; **34**: e14290 [*RCA*] [PMID: 34709712 DOI: 10.1111/nmo.14290] [FullText]

90 **Jungheim M**, Busche A, Miller S, Schilling N, Schmidt-Thieme L, Ptok M. Calculation of upper esophageal sphincter restitution time from high resolution manometry data using machine learning. *Physiol Behav* 2016; **165**: 413-424 [*RCA*] [PMID: 27521686 DOI: 10.1016/j.physbeh.2016.08.005] [FullText]

91 **Rafieivand S**, Moradi MH, Momayez Sanat Z, Asl Soleimani H. A fuzzy-based framework for diagnosing esophageal mobility disorder using high-resolution manometry. *J Biomed Inform* 2023; **141**: 104355 [*RCA*] [PMID: 37023842 DOI: 10.1016/j.jbi.2023.104355] [FullText]

92 **Popa SL**, Surdea-Blaga T, Dumitrascu DL, Chiarioni G, Savarino E, David L, Ismaiel A, Leucuta DC, Zsigmond I, Sebestyen G, Hangan A, Czako Z. Automatic Diagnosis of High-Resolution Esophageal Manometry Using Artificial Intelligence. *J Gastrointestin Liver Dis* 2022; **31**: 383-389 [*RCA*] [PMID: 36535043 DOI: 10.15403/jgld-4525] [FullText]

93 **Popa SL**, Pop C, Dita MO, Brata VD, Bolchis R, Czako Z, Saadani MM, Ismaiel A, Dumitrascu DI, Grad S, David L, Cismaru G, Padureanu AM. Deep Learning and Antibiotic Resistance. *Antibiotics (Basel)* 2022; **11**: 1674 [*RCA*] [PMID: 36421316 DOI: 10.3390/antibiotics11111674] [FullText] [Full Text(PDF)]

94 **Surdea-Blaga T**, Sebestyen G, Czako Z, Hangan A, Dumitrascu DL, Ismaiel A, David L, Zsigmond I, Chiarioni G, Savarino E, Leucuta DC, Popa SL. Automated Chicago Classification for Esophageal Motility Disorder Diagnosis Using Machine Learning. *Sensors (Basel)* 2022; **22**: 5227 [*RCA*] [PMID: 35890906 DOI: 10.3390/s22145227] [FullText] [Full Text(PDF)]

95 **Czako Z**, Surdea-Blaga T, Sebestyen G, Hangan A, Dumitrascu DL, David L, Chiarioni G, Savarino E, Popa SL. Integrated Relaxation Pressure Classification and Probe Positioning Failure Detection in High-Resolution Esophageal Manometry Using Machine Learning. *Sensors (Basel)* 2021; **22**: 253 [*RCA*] [PMID: 35009794 DOI: 10.3390/s22010253] [FullText] [Full Text(PDF)]

96 **Popa SL**, Surdea-Blaga T, Dumitrascu DL, Pop AV, Ismaiel A, David L, Brata VD, Turtoi DC, Chiarioni G, Savarino EV, Zsigmond I, Czako Z, Leucuta DC. Gemini-Assisted Deep Learning Classification Model for Automated Diagnosis of High-Resolution Esophageal Manometry Images. *Medicina (Kaunas)* 2024; **60**: 1493 [*RCA*] [PMID: 39336534 DOI: 10.3390/medicina60091493] [FullText] [Full Text(PDF)]

97 **Wang Z**, Hou M, Yan L, Dai Y, Yin Y, Liu X. Deep learning for tracing esophageal motility function over time. *Comput Methods Programs Biomed* 2021; **207**: 106212 [*RCA*] [PMID: 34126411 DOI: 10.1016/j.cmpb.2021.106212] [FullText]

98 **Farah A**, Abboud W, Shibli F, Savarino V, Marabotto E, Savarino EV, Mari A. Preoperative gastroenterological evaluation for anti-reflux surgery: strengthening surgeon-gastroenterologist collaboration and improving patient selection. *Expert Rev Gastroenterol Hepatol* 2025; **19**: 963-972 [*RCA*] [PMID: 40824004 DOI: 10.1080/17474124.2025.2549377] [FullText]

99 **Ebigbo A**, Mendel R, Scheppach MW, Probst A, Shahidi N, Prinz F, Fleischmann C, Römmele C, Goelder SK, Braun G, Rauber D, Rueckert T, de Souza LA Jr, Papa J, Byrne M, Palm C, Messmann H. Vessel and tissue recognition during third-space endoscopy using a deep learning algorithm. *Gut* 2022; **71**: 2388-2390 [*RCA*] [PMID: 36109151 DOI: 10.1136/gutjnl-2021-326470] [FullText] [Full Text(PDF)]

100 **Ward TM**, Hashimoto DA, Ban Y, Rattner DW, Inoue H, Lillemoe KD, Rus DL, Rosman G, Meireles OR. Automated operative phase identification in peroral endoscopic myotomy. *Surg Endosc* 2021; **35**: 4008-4015 [*RCA*] [PMID: 32720177 DOI: 10.1007/s00464-020-07833-9] [FullText]

101 **Takahashi K**, Sato H, Shimamura Y, Abe H, Shiwaku H, Shiota J, Sato C, Hamada K, Ominami M, Hata Y, Fukuda H, Ogawa R, Nakamura J, Tatsuta T, Ikebuchi Y, Yokomichi H, Terai S, Inoue H. Achalasia phenotypes and prediction of peroral endoscopic myotomy outcomes using machine learning. *Dig Endosc* 2024; **36**: 789-800 [*RCA*] [PMID: 37886891 DOI: 10.1111/den.14714] [FullText]

102 **Geiger A**, Wagner L, Rueckert D, Wilhelm D, Jell A. Detecting and clustering swallow events in esophageal long-term high-resolution manometry. 2024 Preprint. Available from: arXiv: 2405.01126 [cs.CV] [DOI: 10.48550/arXiv.2405.01126] [FullText]

Published by **Baishideng Publishing Group Inc**
7041 Koll Center Parkway, Suite 160, Pleasanton, CA 94566, USA
Telephone: +1-925-3991568
E-mail: office@baishideng.com
Help Desk: https://www.f6publishing.com/helpdesk
https://www.wjgnet.com

© 2025 Baishideng Publishing Group Inc. All rights reserved.